

# A Case of Paraganglioma as an Unusual Tenant of Gallbladder

SNEHLATA HINGWAY<sup>1</sup>, SUHIT NASERI<sup>2</sup>, PRAVIN GADKARI<sup>3</sup>

## ABSTRACT

Gallbladder paraganglioma is an exceptionally uncommon tumour. Paragangliomas are a subset of Neuroendocrine Neoplasms (NENs) called neurogenic NENs that arise from neural crest cells of the neuroectoderm. They present diagnostic challenges due to their uncommon occurrence and non specific clinical manifestations. The paraganglion system consists of two cell types, called chief and sustentacular cells. The most common location of a paraganglioma is the adrenal medulla, defined as pheochromocytoma. Pheochromocytomas, found in the adrenal medulla, are known for their high Catecholamine (CA) production, leading to significant clinical manifestations like hypertension and metabolic disturbances. A 36-year-old female, otherwise asymptomatic, underwent cholecystectomy due to persistent abdominal discomfort in the right hypochondrium for two months. Preoperative imaging demonstrated a gallstone. Laparoscopic cholecystectomy was performed. The pathological analysis following surgery documented the presence of gallbladder paraganglioma and chronic cholecystitis. Immunohistochemically, chief cells displayed widespread positivity for chromogranin, synaptophysin, and sustentacular cells displayed S100 positivity. There are no definitive guidelines for the management of gallbladder paragangliomas due to their rarity. Reporting instances of paraganglioma in the gallbladder is critical to raising clinical awareness, enhancing diagnostic criteria, optimising treatment protocols, and unravelling the underlying molecular mechanisms. All of these efforts are critical for improving patient care and outcomes in treating this uncommon and enigmatic tumour entity.

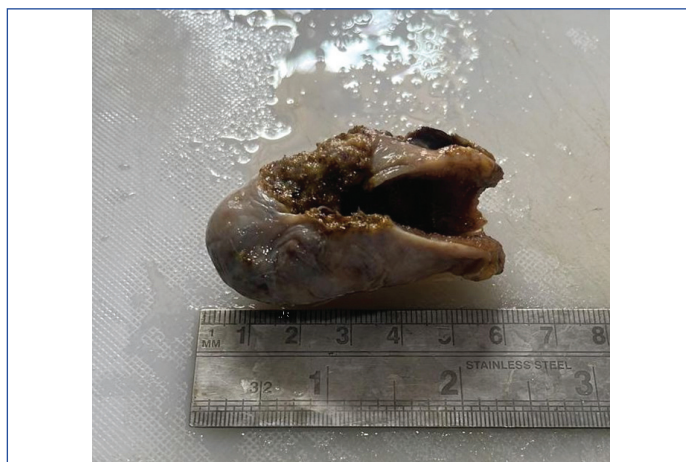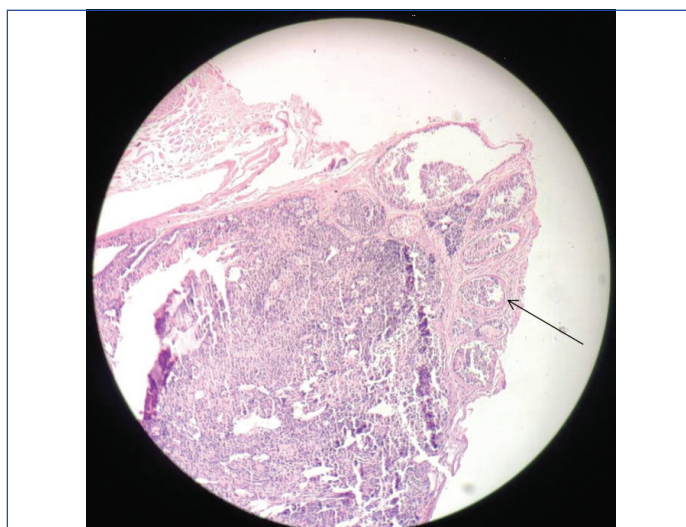
**Keywords:** Cholecystectomy, Histopathology, Neuroendocrine tumour, Paraganglia

## CASE REPORT

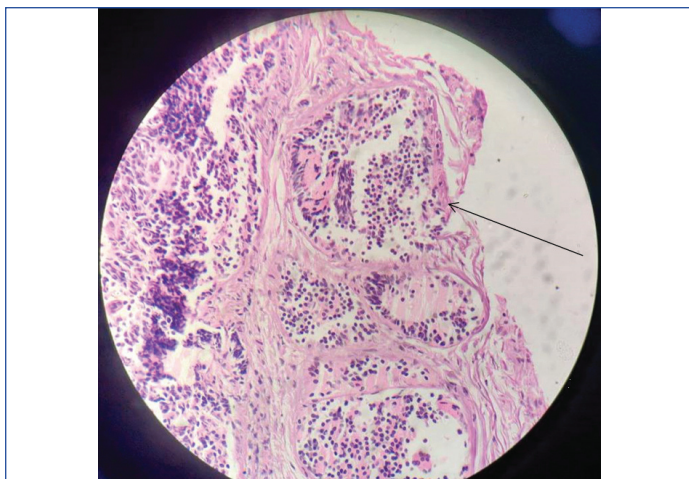
A 36-year-old female presented to the emergency room and was transferred to the Department of Surgery with complaints of chronic abdominal discomfort in the right hypochondrium for two months. She denied having similar complaints in the past. Her vital signs were stable. Laboratory assessments, including a complete blood examination, total bilirubin, C-Reactive Protein, and lipase, revealed no abnormalities, with all results falling within the normal range. An abdominal X-ray revealed a gallstone measuring 10×5 mm. A preliminary diagnosis of cholelithiasis was established, with differentials including acute cholecystitis and eosinophilic cholecystitis. Upon obtaining the patient's written informed consent, a team proficient in advanced laparoscopic techniques performed laparoscopic cholecystectomy. An examination of the frozen section of the excised specimen indicated the presence of a benign tumour and chronic cholecystitis. The excised cholecystectomy specimen was sent for histopathological (Haematoxylin and Eosin (H&E)) analysis. The patient was discharged the day after the procedure, and no complications were observed during the postoperative period.

The cholecystectomy specimen measured 6×2×1 cm. On cut section, a pigmented stone was identified, and bile oozed out. The bladder wall showed mild thickening [Table/Fig-1].

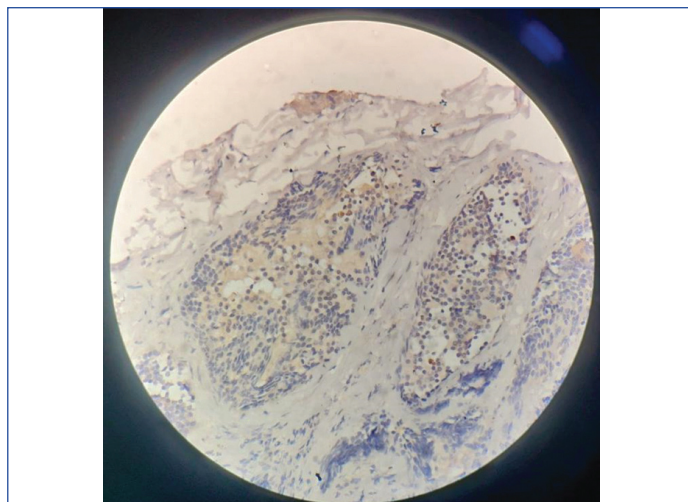
On microscopy, a section from the neck of the Gallbladder demonstrated an encapsulated mass in the muscularis and serosa [Table/Fig-2]. The tumour showed cells in a nesting pattern, separated by fine fibrovascular septa. The cells had a moderate amount of cytoplasm, uniform bland nuclei with salt and pepper chromatin [Table/Fig-3]. Some areas showed spindling of the cells, and focal pseudo-papillae formation were seen [Table/Fig-4]. No mitotic figures, nuclear atypia, or necrosis were observed. Immunohistochemically, the lesion exhibited strong granular cytoplasmic positivity with the neuroendocrine markers synaptophysin and chromogranin A [Table/Fig-5,6]. S100 staining was evident in sustentacular cells [Table/Fig-7].

**[Table/Fig-1]:** Resected specimen of gallbladder.**[Table/Fig-2]:** Encapsulated mass in the muscularis and serosa (H&E, x40).

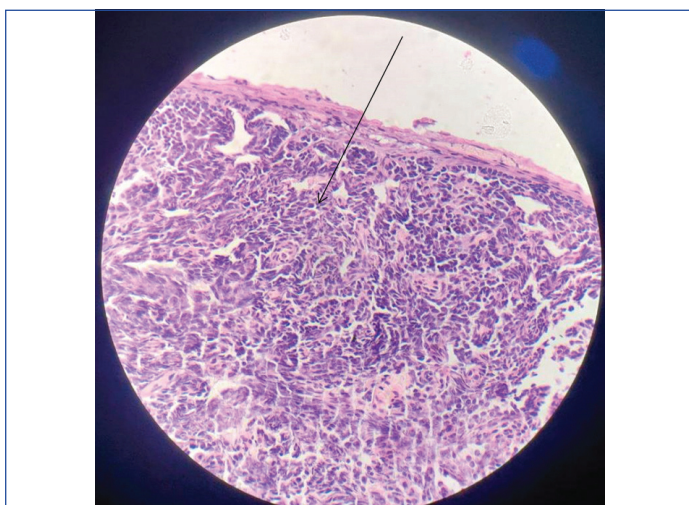




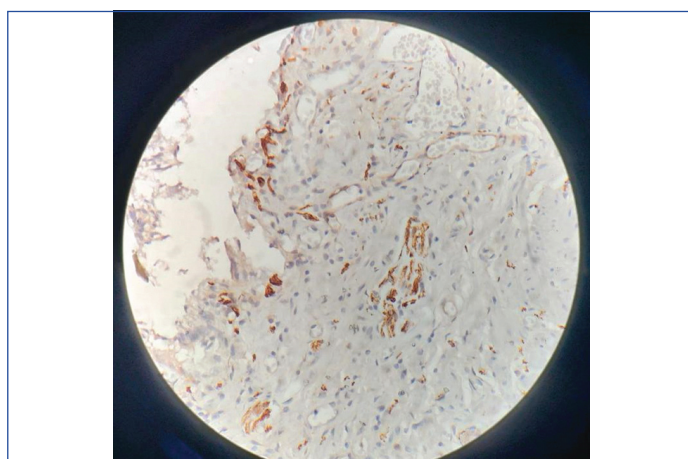
**[Table/Fig-3]:** Tumour shows cells in a nesting pattern, separated by fine fibrovascular septa. (H&E, x200).



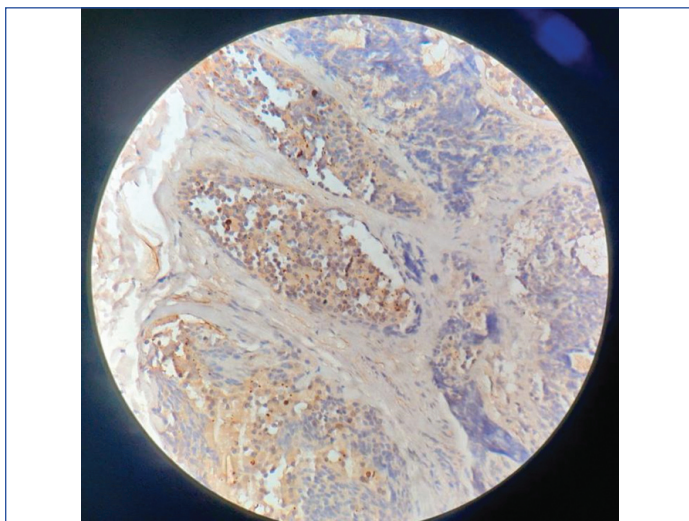
**[Table/Fig-6]:** Paraganglioma with Chromogranin positivity. (H&E, x400).



**[Table/Fig-4]:** Showing spindling of the cells and focal pseudo-papillae formation (H&E, x400).



**[Table/Fig-7]:** Paraganglioma with S100 positivity. (H&E, x400).



**[Table/Fig-5]:** Paraganglioma with Synaptophysin positivity. (H&E, x400).

The diagnosis for the tumour was confirmed by the combined morphological and immunohistochemical features as 'paraganglioma.' The diagnosis based on clinicoradiological analysis was thought to be cholelithiasis, and hence the patient was planned for cholecystectomy. The diagnosis of pheochromocytoma was excluded because this was an extra-adrenal location. Sympathetic paraganglioma has a higher risk of malignant components, which were missing in the reported case. No additional paraganglioma foci were observed in the remaining gallbladder tissue. Background alterations consistent with chronic cholecystitis were present, accompanied by underlying changes associated with cholelithiasis.

The patient under consideration did not have any family history of endocrine neoplasia.

## DISCUSSION

Paraganglia undergo differentiation from neural crest cells in the embryonic phase. Paragangliomas are uncommon tumours that develop from paraganglia [1].

Extra-adrenal paragangliomas are commonly found in typical locations such as the sympathetic plexus in the preaortic and paravertebral regions. Additionally, they are often located in the skull base, encompassing areas around the jugular foramen, ears, and carotid bodies [2]. Gallbladder paragangliomas are exceptionally uncommon. They are either parasympathetic or sympathetic in nature. The majority of parasympathetic paragangliomas are asymptomatic and non secretory with fewer than 5% secreting CAs. Sympathetic paragangliomas, on the other hand, release primarily noradrenaline, causing symptoms similar to pheochromocytoma, such as palpitations and sweating [3]. The majority of paragangliomas occur sporadically. However, approximately 30%-40% of cases are familial and are associated with genetic syndromes, notably Multiple Endocrine Neoplasia (MEN) types 2A and 2B [3]. Paragangliomas in the biliary system are more commonly observed in females and are typically identified in individuals aged between the fifth and sixth decades of life. Due to their non functional nature, these tumours are usually detected as a result of complications [4]. Primary gallbladder paragangliomas are thought to arise from the hepatic plexus primordia that innervates the gallbladder. They are made up of sympathetic and parasympathetic fibres that originate in the vagus nerve of the left and celiac plexus. Primary gallbladder paragangliomas, however uncommon, must be recognised may manifest and should be taken into consideration when evaluating gallbladder lesions differentially [4]. The first documentation of gallbladder paraganglioma can be

Author's name	Year of reporting	Age with sex	Clinical findings	Investigations	Radiological findings	Histopathological findings
Miller TA et al., [5]	1972	57/M	Recurrent haematemesis	Radiology and histopathology	Duodenal ulcer next to scarred duodenal bulb	"Zellballen" structures composed of polygonal cells
Wolff M [8]	1973	32/F	Cholelithiasis	Histopathology	Not mentioned	"Zellballen" structures composed of polygonal cells
Kawabata K [9]	1999	51/F	Mildly elevated transaminases	Histopathology	Gall stones, Hepatobiliary lithiasis	"Zellballen" structures composed of polygonal cells with granular cytoplasm and associated with fine capillary networks
Hirano T [10]	2000	58/F	Right hypochondrial pain	Radiology and histopathology	Lesion in the neck of gallbladder	Polygonal cells with a round to oval nucleus and an ill-defined cytoplasm which was either basophilic, amphophilic granular, clear or vacuolated.
Cho YU et al., [11]	2001	45/F	Intermittent right upper quadrant pain	Histopathology	Not mentioned	Round or polygonal epithelioid cells form small nests in Zellballen patterns, which characteristically appear to be encircled by supporting sustentacular cells and elaborate vasculature.
Mehra S and Chung-Park M [7]	2005	36/M	None	Radiology and histopathology	Normal	The tumour was highly vascular and completely surrounded by a thin fibrous capsule. The tumour cells were arranged in small islands forming Zellballen nests
Sakuma T et al., [12]	2011	38/M	Hepatic hilus tumour	Radiology and histopathology	Heterogenous mass and Cholelithiasis	"Zellballen" structures composed of polygonal cells
Ece I et al., [13]	2015	57/F	Intermittent right upper quadrant pain	Radiology and histopathology	Gallbladder stone with a mass within triangle of calot	Abundant granular basophilic cytoplasm and sustentacular cells around the chief cells. A highly vascular stroma supported the tumoural nests.
AlMarzooqi R et al., [14]	2018	Not mentioned	Right upper quadrant pain	Radiology and histopathology	Gallbladder stone	"Zellballen" structures composed of polygonal cells
Abdul Sater Z et al., [15]	2019	36/M	Mild hypertension and tinnitus	Radiology and histopathology	A lesion with arterial enhancement to the gallbladder	nested arrangement of paraganglioma cells with fine fibrovascular septa. Neoplastic cells are monomorphic with round nuclei and inconspicuous nucleoli.
D'John M and Jabbar F [16]	2020	72/F	Recurrent biliary colic	Radiology and histopathology	Mildly dilated gallbladder	Microscopic findings of the polypoid mass showing a zellballen pattern
Shreya S et al., [4]	2021	72/F	Discomfort in both ears accompanying by hearing loss	Radiology and histopathology	A lesion in the neck of gallbladder	"Zellballen" structures composed of polygonal cells

[Table/Fig-8]: Published cases in literature [4,5,7-16].

attributed to the report by Miller TA et al., in 1972 [5]. Most instances are discovered inadvertently following cholecystectomy performed for reasons such as cholelithiasis and abdominal pain. The vast majority of paragangliomas are benign in nature, with approximately 10% being malignant [5]. Remarkably, all these tumours lack functionality. As a result, they resemble chromaffin-negative extra-adrenal tumours located in the head, neck, and mediastinal region, differing from extra-adrenal retroperitoneal paragangliomas [6]. Microscopic differentiation between benign and malignant paragangliomas lacks specific morphologic criteria. The classification is determined by the presence or absence of metastatic disease. Indications have been reported suggesting that malignancy may be anticipated with features such as coarse nodularity, confluent necrosis, and reduced neuropeptide expression [6]. Paragangliomas can also manifest as part of Carney's triad. Familial paragangliomas are typically identified after the age of 30 years although occurrences have been observed in the early teenage years. The characteristic features of familial tumours include multicentricity and bilaterality. To date, there has been only one reported case of a paraganglioma in the biliary system with a familial association [7]. It is advised to conduct molecular genetic screening for mutations of the genes Succinate Dehydrogenase subunit B (SDHB), SDHC, and SDHD in all head and neck paraganglioma patients. When a mutation is discovered, the patient with the condition should have a thorough clinical examination, including an Magnetic Resonance Imaging (MRI) with contrast medium for the head, neck, thorax, and belly, as well as an evaluation of CAs. Due to their rarity, there are no established guidelines for the management and surveillance of incidental gallbladder paragangliomas. In all the cases documented in the literature, cholecystectomy has been performed [Table/Fig-8] [4,5,7-16].

CONCLUSION(S)

The present case highlights the importance of meticulous histopathological examination in diagnosing gallbladder paran-

gliomas, emphasising the need for awareness among clinicians and pathologists. Understanding the nuances of its histopathology is paramount. The rarity of gallbladder paragangliomas underscores the importance of reporting such cases in the medical literature to contribute to the collective knowledge base and enhance understanding of this uncommon entity. Sharing clinical experiences and outcomes can help guide future diagnostic and therapeutic approaches, ultimately improving patient care and prognosis.

REFERENCES

[1] Rodriguez-Cuevas H, Lau I, Rodriguez HP. High-altitude paragangliomas diagnostic and therapeutic considerations. *Cancer*. 1986;57(3):672-76.

[2] Mahin HH, Sarofim M, Jaber M. Paraganglioma of the gallbladder: An extremely rare pathology. *Int J Case Rep*. 2019;3(2):6.

[3] Zakkor MD, Swed S, Salem R, Zayat H, Sultan R, Al Hussein H, et al. Intra-abdominal paraganglioma and primary thyroid lymphoma in a single patient: The first case report. *Case Rep Oncol*. 2023;16 (1):753-58.

[4] Shreya S, Kashikar R, Shraddha SR, Shrinivas D. Case of the very rare gallbladder paraganglioma. *Indian J Radiol Imaging*. 2021;31(03):693-96.

[5] Miller TA, Weber TR, Appelman HD. Paraganglioma of the gallbladder. *Arch Surg*. 1972;105(4):637-39.

[6] Linnoila RI, Keiser HR, Steinberg SM, Lack EE. Histopathology of benign versus malignant sympathoadrenal paragangliomas: Clinicopathologic study of 120 cases including unusual histologic features. *Hum Pathol*. 1990;21(11):1168-80.

[7] Mehra S, Chung-Park M. Gallbladder paraganglioma: A case report with review of the literature. *Arch Pathol Lab Med*. 2005;129(4):523-26.

[8] Wolff M. Paraganglioma of the gallbladder. *Arch Surg*. 1973;107(3):493.

[9] Kawabata K. Paraganglia of the gallbladder: A report of two cases with an immunohistochemical study. *Pathol Res Pract*. 1999;195(11):781-86.

[10] Hirano T. Paraganglioma of the gallbladder: Report of a rare case. *Am J Gastroenterol*. 2000;95(6):1607-08.

[11] Cho YU, Kim JY, Choi SK, Hur YS, Lee KY, Kim SJ, et al. A case of hemorrhagic gallbladder paraganglioma causing acute cholecystitis. *Yonsei Med J*. 2001;42(3):352-56.

[12] Sakuma T, Hirota M, Ohashi H, Kakudo K, Kawano K. Extensive ganglioneuromatosis of gallbladder. *Int J Surg Pathol*. 2011;19(4):524-26.

[13] Ece I, Alptekin H, Çelik ZE, Çahin M. Gallbladder paraganglioma. *Ulus Cerrahi Derg*. 2015;31(4):244-46.

[14] AlMarzooqi R, AlJaberi L, Rosenblatt S, Plesec T, Berber E. A rare case of paraganglioma of the cystic duct. *Int J Surg Case Rep*. 2018;52:16-19.

[15]

Abdul Sater Z, Jha A, Mandl A, Mangelen SK, Carrasquillo JA, Ling A, et al. Gallbladder paraganglioma associated with SDHD mutation: A potential pitfall on (18)F-FDOPA PET imaging. Nucl Med Mol Imaging. 2019;53:144-47. Doi: 10.1007/s13139-018-0558-1.

[16]

D'John M, Jabbar F. Primary gallbladder paraganglioma: A case report and review of literature. Int J Surg Case Rep. 2020;75:451-53. Doi: 10.1016/j.ijscr.2020.09.095.

PARTICULARS OF CONTRIBUTORS:

1. Professor, Department of Pathology, Datta Meghe Institute of Higher Education and Research, Wardha, Maharashtra, India.
2. Resident, Department of Pathology, Datta Meghe Institute of Higher Education and Research, Wardha, Maharashtra, India.
3. Professor, Department of Pathology, Datta Meghe Institute of Higher Education and Research, Wardha, Maharashtra, India.

NAME, ADDRESS, E-MAIL ID OF THE CORRESPONDING AUTHOR:

Dr. Suhit Naseri,  
Resident, Department of Pathology, Datta Meghe Institute of Higher Education and Research, Wardha-442107, Maharashtra, India.  
E-mail: drsuhitnaseri@gmail.com

PLAGIARISM CHECKING METHODS: [\[Jain H et al.\]](#)

- Plagiarism X-checker: Dec 09, 2023
- Manual Googling: Feb 20, 2024
- iThenticate Software: Apr 01, 2024 (13%)

ETYMOLOGY: Author Origin

EMENDATIONS: 6

AUTHOR DECLARATION:

- Financial or Other Competing Interests: None
- Was informed consent obtained from the subjects involved in the study? Yes
- For any images presented appropriate consent has been obtained from the subjects. Yes

Date of Submission: **Dec 08, 2023**

Date of Peer Review: **Feb 15, 2024**

Date of Acceptance: **Apr 02, 2024**

Date of Publishing: **Jul 01, 2024**